

the holistic smile

Sydney cosmetic dentist **Dr Michael Tam** believes in taking a holistic approach to the process of planning and creating an attractive smile. Francis Herron reports.

The process of smiling brings into play nearly all the elements of a person's face. It involves the facial muscles, mouth and lips as well as the teeth and gums. It is possible to make incremental improvements to one's appearance with individual procedures like teeth whitening or veneers, but the whole smile is more than just the sum of its parts.

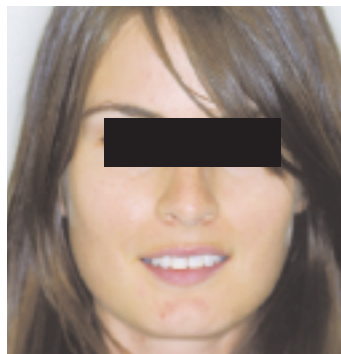Designing a sensational smile is more about the face as a whole than fixing individual teeth,' says Sydney cosmetic dentist Dr Michael Tam. He stresses the critical importance of a comprehensive initial smile assessment, smile design and treatment planning process, in order to establish what the patient's goals are and match the treatment to achieve

total patient satisfaction. 'The smile evaluation process is what differentiates a good cosmetic dentist,' says Dr Tam. 'It comprises assessing all the areas that may impact on the desired outcome in achieving a beautiful smile – from attaining correct diagnostic records to utilising cosmetic digital imaging software to ensure patients are able to visualise the final result prior to starting treatment. It entails detailed discussions about the type of smile the patient wants, treatment planning and explaining realistic outcomes. It also comprises informing patients about what is actually involved in each procedure, including scheduling requirements, costings, and the possible risks and complications.'

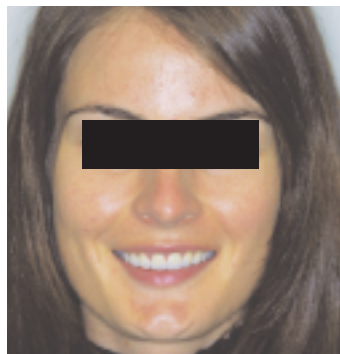
Smile design is critical to create an outcome that is customised for each individual person. There are a number of visual techniques that a cosmetic dentist needs to be aware of. For example, the shape of the patient's face will affect the chosen shape of the teeth. If a patient has a round face, creating long, square-shaped teeth will ultimately have a slimming effect on their face. Another indication of age is the dark, negative space seen in the back corners of the mouth when a person smiles. A more masculine appearance can be imparted by making the teeth squarer with a straighter smile. Deeper, more rounded curves and a more curved smile line will achieve a more feminine look.

While thorough prior assessment and treatment planning are key factors, the success and longevity of aesthetic treatment is directly related to good oral health. Dr Tam says it is essential that the patient's mouth is healthy and long-term stability and maintenance is addressed. For example, assessment of any grinding or para-functional habits, how teeth come together, whether there are teeth missing which may lead to a 'collapsed bite', and the requirement of a harmonious physiological balance with the facial and 'biting muscles' are all of vital importance. The soft tissues are also assessed, especially in regard to lip shape,

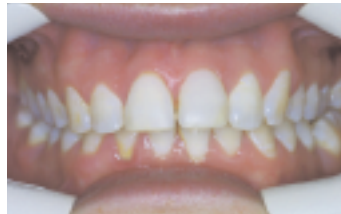case study 1



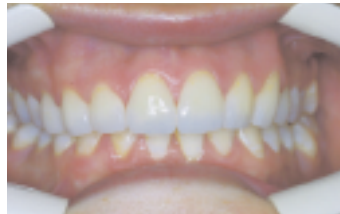BEFORE Prominent protruding teeth with mish mash of colours and bonding



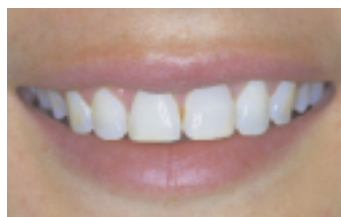AFTER Patient desired a beautiful yet more natural smile with eight porcelain veneers by Dr Tam



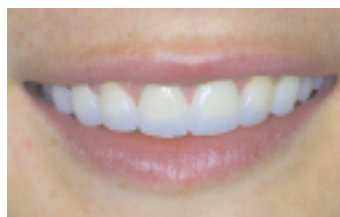BEFORE



AFTER



BEFORE



AFTER

How to find a good cosmetic dentist

Take your time. Cosmetic dentistry is normally an elective procedure and not an emergency. For something as important as this, research time up front will pay great dividends towards your understanding and emotional comfort later. It is important to check that the cosmetic dentist you are considering:

- Performs your chosen procedure on more than a regular basis
- Has before and after albums showing their clinical expertise
- Offers value for money
- Is honest in their assessment of your needs and their ability to meet your expectations
- Has an artistic eye. Excellent cosmetic dentistry requires a highly sophisticated artistic sense. Your dentist must have a clear vision of what is possible, as well as being able to communicate well with the cosmetic ceramist
- Takes a multi-discipline approach. The cosmetic

dentist must utilise a network of specialists and, if necessary, refer to them in consultation with you

- Has a good chair-side manner so you feel comfortable and relaxed
- Gives you a good impression. Do you like the appearance and feel of the practice? Are the staff members professional and caring? Is the team well trained?
- Explains all options, including any possible risks and complications
- Is committed to and passionate about continuous education in their field
- Belongs to affiliations and associations, is on the lecture circuit or regularly attends aesthetic updates locally and overseas.

Dr Michael Tam has performed cosmetic dental procedures on national TV, in Channel Seven's The Body Specialists on Thursday nights. During his appearances he has discussed in-chair tooth whitening systems and performed smile design and porcelain veneers treatment for two patients.

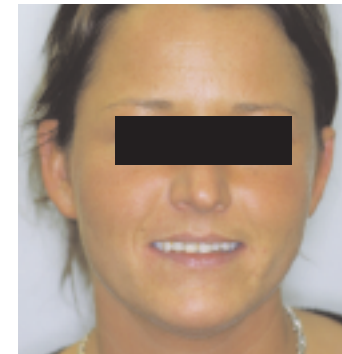length, symmetry and bulk. The gum lines, smile lines and gingival display are critical ingredients in achieving more pleasing proportions. Shape, form and alignment may also be far more important than colour.

There is a range of cosmetic procedures available to patients. 'Cosmetic bonding can be used to close gaps and repair chipped or fractured teeth, and composite or porcelain restorations,' Dr Tam explains. 'These are an attractive, more natural looking option to unsightly dark amalgam fillings.'

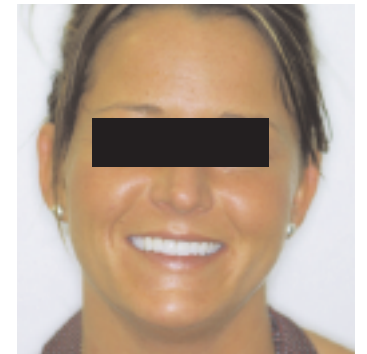Veneers are made either from natural-looking, durable porcelain or tooth-coloured filling material and are designed to cover teeth that are severely stained or discoloured. Crowns are placed when there is very little natural tooth left and may act to realign teeth and to protect teeth long term. Gum contouring, also called 'crown lengthening' or 'gum lifts', can be used to lengthen teeth and reduce a 'gummy' smile.

Dr Tam explains, 'It is essential for patients to select a practitioner who has a special interest in and commitment to cosmetic and reconstructive dentistry. The practitioner must not only have the technical expertise to be able to create a new smile but also have an artistic understanding of the features of the face to be able to make your new smile beautiful.' **acsm**

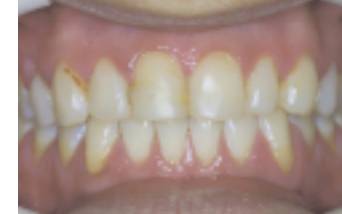case study 2



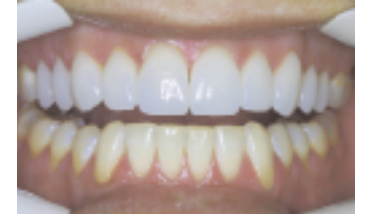BEFORE Discoloured, stained composite veneers, incorrect proportions, form and harmony



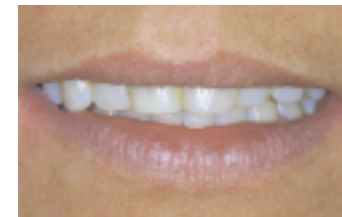AFTER Patient desired a beautiful yet Hollywood smile with 10 porcelain veneers by Dr Tam



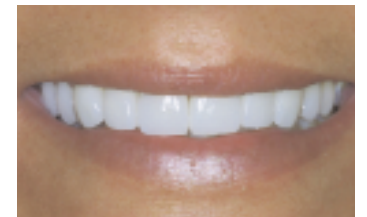BEFORE



AFTER



BEFORE



AFTER